

THE MANAGEMENT OF THE COMPROMISED CORNEA WITH CONTACT LENSES

Dr Elisabeth Millis discusses how contact lenses are used in the treatment of corneal conditions.

Contact lenses have been used in the treatment of corneal conditions for many years and are used to relieve symptoms, particularly pain, and improve vision. Lenses used for this purpose are referred to as therapeutic, or bandage, lenses. In many cases they need to be worn overnight, on an extended wear basis, because the patient has difficulty handling the lens, or because of the demands of the ocular condition. The eyes that are fitted have, by definition, abnormal corneas and are at greater risk of complication than normal eyes. It is therefore particularly important to consider corneal oxygenation and wetting.

Lens types

An accurate assessment of the corneal condition and careful patient selection will determine the type of lens used. All types may be fitted including RGP and scleral lenses but the lenses used most commonly are soft, hydrogel lenses.

Therapeutic soft contact lenses (TSCLs)

TSCLs may be high water content lenses such as Sauflon PW (79 per cent water content) [Cantor and Nissel] with a

centre thickness of 0.18 and often a plano power, or they may be thinner lower water content lenses that are good for protection and healing. Very thin lenses may make handling difficult for the patient.

Conventional lenses

TSCLs may be conventional lenses that are worn on a daily basis for up to one year. If used for extended wear (EW) they may need to be worn continuously, day and night, for periods up to three months. This is the maximum time that should be allowed between visits by these patients, but it is often found necessary to review them more frequently. Despite the advent of disposable lenses, these lenses still have a major part to play in managing the compromised cornea. TSCLs, while often afocal, can be powered and it is possible to fit high water content astigmatic soft lenses on an EW programme if the patient is kept under careful observation. High water content lenses are more prone to deposit formation, which often causes problems in the elderly with dry eyes.

Disposable lenses

TSCLs may also be fitted on a frequent replacement schedule using commercially available 'disposable' lenses such as Acuvue (Vistakon) or Seequence (Bausch & Lomb). These lenses are especially useful on damaged corneas as they are changed weekly, or even daily. They do not build deposits to the same extent as conventional lenses and so maintain better oxygen transmission and show fewer solution sensitivity reactions. They may be difficult to handle as they are often thinner than conventional lenses and there are fewer parameters available. They are not suitable in cases which require the lens to remain undisturbed for considerable periods.

Silicone rubber lenses

These lenses have been used as therapeutic lenses but are uncomfortable to wear as they wet badly and rapidly collect deposits. Patients and clinicians find them difficult to handle and it may be necessary to remove the lens using sterile forceps.

Silicone hydrogel lenses

These lenses (Purevision [Bausch and Lomb], Night and Day [Ciba Vision]) are designed for EW and would appear to have a place in the range of therapeutic lenses as they have very high oxygen transmission. They are licensed for seven day wear in the USA and 30 days in Europe. These lenses have only become available in the last eighteen months and experience in their use is limited, particularly with the compromised cornea. At the time of writing they are only available in minus powers and in one base curve.

Rigid gas permeable (RGP) lenses

RGP lenses are sometimes used for therapeutic purposes. They are obtainable with high gas permeability but need to be fitted with a large total diameter in order to minimise movement. If these cannot be tolerated a hybrid lens with a gas permeable centre and hydrogel skirt may be a solution (Figure 1).

Scleral lenses

Scleral, or haptic, lenses were the earliest lenses to be used to treat damaged corneas. They are now available in gas permeable materials as well as the older PMMA. They are useful in a variety of conditions, particularly dry eyes.

Collagen shields

These are made from porcine collagen and are biodegradable on the eye but they may dissolve in a variable manner and the remnants may be difficult to remove. Whilst in place they reduce visual acuity as they are translucent but not transparent. They have been used for drug delivery.

Fitting soft therapeutic lenses

TSCLs should be fitted loose on normal epithelium, particularly in a dry eye, as the lens may dehydrate and tighten on the eye. The lens should be fitted with minimal movement on loose epithelium to encourage healing.

The lenses are large, 15.5mm diameter or more, with the appropriate BOZR. If it is possible to obtain keratometry readings the lenses are fitted 1mm flatter than mean K. It is desirable to maintain a stock of TSCLs and lenses with BOZR of 8.4 and 15.5mm diameter with plano power are most useful. If a powered lens, or a lens of different parameters is needed it is often possible to fit a stock lens initially and exchange it later.

All lenses, particularly EW lenses, should be applied in as sterile a manner as possible. Hands should be washed, and dried carefully on a lint-free towel, immediately prior to inserting the lens. The lens is removed from the container with a sterile rod. Care should be taken to avoid touching the posterior surface of

the lens and to avoid the lens touching lids or lashes. Topical local anaesthetic drops should be avoided unless they are essential as they increase further the risk of damage from foreign bodies, and are toxic to the epithelium.

If conventional lenses are used they should be changed every three months, or earlier if indicated. The lens must then be cleaned and sterilised and retained for use by that individual. The patient will need spare lenses to alternate with the original, and this increases the cost. The use of frequent replacement lenses obviates the necessity for this but may mean the patient attending more often if they are unable to handle the lens.

It is helpful to lubricate the eye well with the N-saline before attempting to remove a lens that overlies loose epithelium, in order to reduce the risk of detaching the epithelium

Management of TSCL

The patient should be given a sufficient supply of the appropriate solutions and advice as to their use if the patient is inserting and removing the lens. For those wearing EW lenses they should be instructed to blink, by completely closing and opening their eyes, 10-20 times on waking after the application of N-saline drops. This has the effect of cleaning the lens of overnight debris, and mobilising the lens on the eye.

EW patients should be supplied with a contact lens case and multipurpose disinfecting solution into which the lens may be placed in the event of the lens being removed or lost from the eye. They must return the lens to the practice for return to the manufacturer, if necessary, for cleaning and sterilisation and not allow the lens to be inserted directly from the disinfecting solution.

Follow-up visits should be scheduled for one day after fitting to ensure the lens has not tightened on the eye, and then one week and one month later. If the lens is to be worn for several months or longer, and there are no problems, the patient may be reviewed at three monthly intervals.

Fitting scleral lenses

The fitting of scleral lenses is usually undertaken by specialist contact lens practitioners. They are fitted by either impression moulding techniques or using preformed lenses. Large (17.20mm) diameter, fenestrated, semi-scleral RGP lenses have been reported as successful in fitting post-keratoplasty patients¹.

Indications for TSCLs - pain relief

The major indication for a bandage contact lens is the relief of pain, and the most common condition for which they are used is bullous keratopathy (Figure 2).

Bullous keratopathy results from decompensation of the corneal endothelium leading to stromal and,

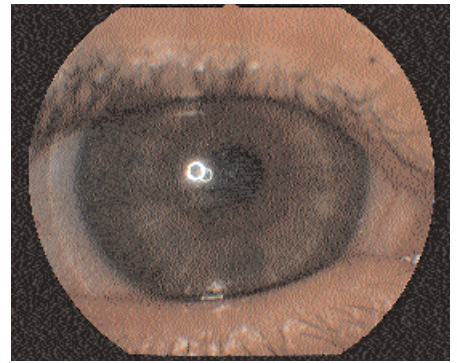


Figure 1: Hybrid lens on corneal graft.

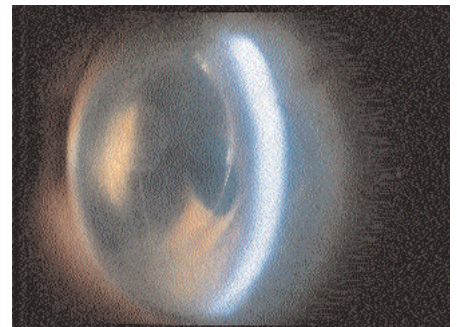


Figure 2: Fuch's endothelial dystrophy with bullous keratopathy.

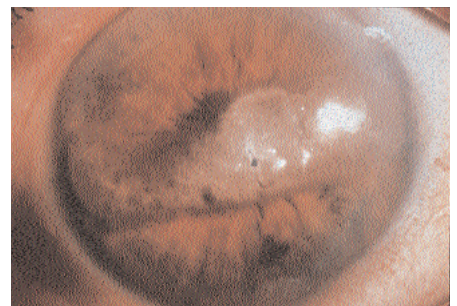


Figure 3: Band shaped degeneration.

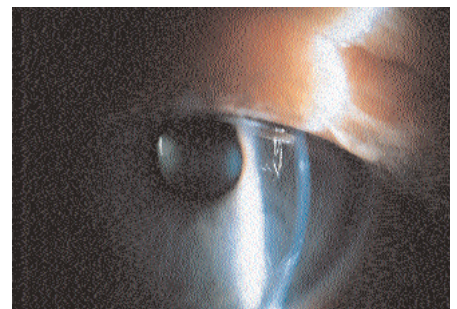


Figure 4: Corneal graft with raised area at graft/host junction and small corneal opacity.

eventually, epithelial oedema. Blister-like bullae form that rupture, exposing corneal nerve endings and resulting in pain. Hypertonic (5 per cent) saline drops may help in the early stages but a TSCL is more effective as it protects the nerve endings and flattens the bullae. Pain relief occurs rapidly after application of the lens and vision often improves.

Healing abnormal epithelium - recurrent corneal erosions²

These may resolve following the application of a TSCL that must be worn for at least 2-3 months. If the eye is dry a high water content lens with the application of copious lubricants may be fitted, but if there is an adequate tear film a thin lens may be preferable. Topical antibiotics may be applied. When the initial period of wear is completed the lens is carefully removed. Copious lubricants are still necessary, particularly at night to prevent the lids adhering to the new epithelium and detaching it as the eyes open on waking. If treatment with a contact lens fails anterior stromal puncture or excimer laser may result in healing.

Corneal epithelial dystrophy

Cogan's, Meesman's, Reis-Buckler's and map-dot-fingerprint dystrophies may all benefit from the application of a thin TSCL.

Herpes simplex

A thin TSCL may be of use when there is a recurring epithelial defect without evidence of active virus. The lens is used in conjunction with topical antibiotics and cyclopentolate.

Herpes zoster

In this disease the epithelial defect is the consequence of an anaesthetic cornea. If a TSCL is used it must be with great care and under close supervision and may lead to an increase of epithelialisation.

Corneal burns

These may be due to acids, alkalis or irradiation. They cause a persistent epithelial defect. A high water content or silicone rubber or lens may be applied. Lenses are fitted with virtually no movement to minimise damage to the epithelium. Conjunctival adhesions may be lysed with a sterile glass rod and a scleral shell may be needed in some cases to maintain the fornices.

Wet filamentary keratitis

A thin lens may relieve symptoms and encourage healing. Filaments should be removed before applying the lens. A lens should not be used in a dry eye.

Corneal melting

This may occur in patients with systemic collagen vascular disease including rheumatoid arthritis, polyarteritis nodosa, systemic lupus erythematosus and Wegener's granulomatosis. There is an acute, severe melting of the clear cornea, which may result in a descemetocele or even perforation. Bandage lenses may promote healing in these cases.

Neurotrophic keratitis

Very great care must be taken in fitting an anaesthetic eye with a contact lens as the risks of infection are considerable, particularly in a dry eye. Exposure

keratitis is better treated with a tarsorrhaphy or by inserting a gold weight in the upper lid to create an iatrogenic ptosis.

Thygeson's superficial punctate keratitis

Temporary relief may be obtained by fitting a thin soft lens but the condition is likely to recur once the lens is removed.

Irregular surface conditions

Discomfort from band-shaped degeneration (Figure 3), and Salzmann's nodular dystrophy may be relieved by a bandage lens until the irregularity can be removed surgically.

Protection of normal epithelium - trichiasis

A large, thin, low water content lens can be applied to prevent discomfort as a temporary measure before surgery or if surgery is not indicated.

Protection of graft epithelium

Protection (Figure 4) can be afforded with a high water content lens with frequent lubrication. Before fitting any lens to a graft the clinician should examine any sutures present. It may be possible if fitting a lens for purely refractive purposes to wait until the sutures are removed but this is not the case with a TSCL. All sutures must be buried and intact. They must not be loose, broken or protruding or they may act as a wick for infection.

Protection in the dry eye

If drops can be applied at frequent intervals a high water content lens may be tried, if not a thin, low water content lens may be more successful. Silicone rubber lenses do not absorb tears but their disadvantages have been discussed above. Scleral lenses may provide a larger fluid reservoir. In all cases prophylactic antibiotics and frequent supervision are necessary.

Moulding and splinting

Bandage lenses may be used to mould tilted grafts³, to heal deep ulcers and descemetoceles and to cover wound leaks. Splinting impedes the flow of aqueous through the wound allowing it to heal, and prevents the ulcer bed buckling. They may also be applied over cyanoacrylate glue used to seal corneal lesions to prevent it being dislodged.

Refractive surgery

Combined with non-steroidal anti-inflammatory drugs TSCLs are used to reduce post-operative discomfort and pain after refractive surgery.

Drug delivery

Soft contact lenses and collagen shields can be soaked in a solution of a drug before applying the lens to the eye. This will provide a longer period of application for the drug and may prevent

unnecessary distress caused by applying drops throughout the night. Most reports refer to the application of antibiotics^{4,5}.

Complications

These are the same as for most contact lens wear but the risk of deposits, hypoxic oedema, corneal vascularisation, sterile infiltrates and microbial keratitis are greater. These can be minimised by ensuring that the patient understands the need for treatment associated with the lens, has rapid emergency access to ophthalmic care and can attend the clinic regularly.

The use of concurrent topical medication is often queried. The greatest risk is of ocular redness and irritation from benzalkonium chloride, which is a common preservative in eyedrops. It is preferable to use preservative free drops when possible but if these are not available and the treatment is necessary then drops must be applied.

Therapeutic lenses are a very rewarding area for the contact lens practitioner but demand close co-operation between lens fitter and ophthalmologist and the availability of both. For this reason they are often best undertaken in a hospital environment.

References

1. Vreugdenhil, W, Geerards, AJM, Vervaeet, CJW. 1998. *A new rigid gas permeable semi-scleral contact lens for treatment of corneal surface disorders*. Contact Lens and Anterior Eye 21(3)85-88.
2. Liu C, Buckley R. 1996. *The role of the therapeutic contact lens in the management of corneal erosions: A review of management strategies*. CLAO J 22 (1) 79-82.
3. Mannis MJ, Zadnik K. 1988. *Hydrophilic contact lenses for wound stabilisation in keratoplasty*. CLAO J 14(4) 199-202.
4. Taravella M, Stepp P, Young D. 1998. *Collagen shield delivery of tobramycin to the human eye*. CLAO J 24(3) 166-168.
5. Kalayci D, Basci N, Kortunnay S *et al*. 1999. *Penetration of topical ciprofloxacin by presoaked medicated soft contact lenses*. CLAO J 25(3) 182-184.

Further reading

- Buckley RJ, Pullman KW. 1995. *Scleral contact lenses*. In Contact Lenses: The CLAO Guide to basic Science and Clinical Practice ED Kastl PR, Vol, pp197-221, Kendal/Hunt.
- Jackson AJ, Surton JE, Frazer DG, Morrison E. 1996. *Therapeutic contact lenses and their use in the management of anterior segment pathology*. J British Contact Lens Assn 19(1) 11-19.

Dr Elisabeth Millis, MD, DO, MRCOPHth, is in private practice in London. Formerly Director of the Contact Lens Clinic, Western Eye Hospital, London. ■